

Cyanoacrylate Surgical Glue as an Alternative to Suture Threads for Mesh Fixation in Hernia Repair

Paola Losi, B.S.C.S.,*¹ Silvia Burchielli, Vet.M.D.,† Dario Spiller, B.S.C.S., Ph.D.,* Valentina Finotti,*
Silvia Kull, M. Eng.,* Enrica Briganti, B.S.C.S., Ph.D.,* and Giorgio Soldani, B.S.C.S.*

*Laboratory for Biomaterials & Graft Technology, Institute of Clinical Physiology CNR, Massa, Italy; and †Fondazione Toscana Gabriele Monasterio per la Ricerca Medica e di Sanità Pubblica, Pisa, Italy

Submitted for publication January 29, 2010

Background. In recent years, the use of synthetic glues has become an established practice in several areas of surgical treatment. For example, they are used in open and laparoscopic surgery and in digestive tract endoscopy, interventional radiology, and vascular neuroradiology. The experiments in this study were aimed at elucidating that suture-based permanent mesh fixation can be replaced by fixation with N-butyl 2-cyanoacrylate glue (Glubran2) for surgical repair of abdominal wall hernias.

Materials and Methods. In 25 Wistar rats, two hernia defects (1.5 cm in diameter) per animal were created bilaterally in the midline of the abdominal wall. The peritoneum was spared. The lesions were left untreated for 10 d to achieve a chronic condition. Then the defects were covered with TiMESH extralight (2 × 2 cm) and fixed by 30 μL of Glubran2 or traditional suture. The time points of sacrifice were 17 and 28 d, 3, 4, and 5 mo. At autopsy, histology and immunohistochemistry were performed to evaluate the inflammatory response and the presence of apoptotic cells respectively.

Results. Mesh fixation was excellent in all samples at each time point. At application sites, the inflammatory reaction was mild with a small number of macrophages and vascularized connective tissue presence around glue and mesh threads. Glue residues were observed in histologic sections at each time point. No presence of apoptotic cells was found.

Conclusions. This study demonstrated that Glubran2 can effectively replace traditional suture in mesh fixation without affecting tissue healing and determining

a physiological inflammatory reaction at the abdominal wall site. © 2010 Elsevier Inc. All rights reserved.

Key Words: cyanoacrylate glue; hernia repair; mesh fixation; inflammatory reaction.

INTRODUCTION

Laparoscopic hernia repair is an effective technique, offering more rapid recovery and less pain than with the traditional open approach; recurrence rates are equivalent to those of the traditional open approach [1, 2]. The current methods of laparoscopic hernia repair involve the application of a preperitoneal prosthetic mesh over the hernia spaces, creating a tension-free repair [3, 4]. The mesh is fixed in place using metal staples to prevent graft displacement, with consequent hernia recurrence [5]. Laparoscopic herniorrhaphy is not devoid of complications. Some of these complications are inherent to the use of the staples and include sensory nerve entrapment with neuralgia, bleeding, hematomas, and chronic unexplained groin pain attributed to staples fixed in Cooper's ligament [5–7].

The complications associated with stapled mesh fixation in laparoscopic hernia repair led to consideration of alternative methods of fixation using tissue sealants. These products can be divided into three main categories: synthetic glues (e.g., cyanoacrylate based), biologic products (e.g., fibrin), and genetically engineered polymer protein glues [8].

Biological sealants such as fibrin sealant have a long history in surgery, where they are used primarily for sealing and hemostatic purposes. Their exceptional safety record is attributable to their complete biodegradability and physiologic mechanism of action. Both clinical and experimental trials demonstrate that fibrin

¹ To whom correspondence and reprint requests should be addressed at Laboratory for Biomaterials and Graft Technology, Institute of Clinical Physiology CNR, via Aurelia Sud, 54100 Massa (MS), Italy. E-mail: losi@ifc.cnr.it.

sealant is a feasible option for mesh fixation in hernia repair [9–11].

Acrylic adhesives or cyanoacrylates form a category of substances extremely interesting for clinical applications. They are synthesized as monomers by condensation of a cyanoacetate with formaldehyde in the presence of catalysts and the adhesive film develops by fast polymerization (5–60 s) triggered by hydroxyl groups on the surfaces to be glued [12].

Synthetic cyanoacrylates are promoted for hernia mesh fixation. However, their surgical use is not widely accepted because of reported cytotoxicity and the lack of published studies outlining the potential side effects of cyanoacrylate glue for mesh sealing [13–15].

Fixation of Ti-Mesh with fibrin sealant and staples was previously tested, and favorable results were published [11]. The controversial results from the application of cyanoacrylate-based glues demanded further experimental investigation before their introduction to the clinical routine of hernia repair [16–18].

The aim of this study was to investigate in rat animal model the efficacy of the use of a small amount of modified n-butyl-2-cyanoacrylate (Glubran2) in abdominal mesh fixation as a feasible alternative to sutures and staples. Glubran2 is a class III medical-surgical product (for internal and external surgical use) which owns outstanding haemostatic and adhesive properties and, once set, produces an effective antiseptic barrier against infectious agents or pathogens commonly found in surgical settings. At the present it is used in open and laparoscopic surgery, digestive tract endoscopy, interventional radiology, and vascular neuroradiology.

MATERIALS AND METHODS

Experimental Animals

Twenty-five male Wistar rats weighting 180 to 220 g were sacrificed for this study. Five different groups were established on the basis of observation time: 17 d ($n = 4$), 28 d ($n = 7$), 3 mo ($n = 6$), 4 mo ($n = 4$), and 5 mo ($n = 4$). All the animals were caged under constant light and temperature conditions during the experimentation in accordance with the guidelines from Ministero della Salute–Dipartimento della Sanità Pubblica Veterinaria, la Nutrizione e la Sicurezza degli Alimenti, which approved this study, based on the Italian Legislative Decree 116/92 regarding animal experimentation.

Surgical Procedure

Anesthesia was induced with sodium thiopental (40 mg/kg) and xylazine (10 mg/kg) i.p. The ventral abdominal wall was shaved and a 5-cm midline incision was made. Under sterile conditions 1.2 cm diameter round defects were created bilaterally by resection of the rectus abdominis muscles using microsurgical technique (Fig. 1). The peritoneum below the muscle was preserved. The skin incision was closed with nonresorbable suture material. The animals were single-caged and allowed to recover for 10 d. This interval ensured treatment of defects free of acute inflammatory response.

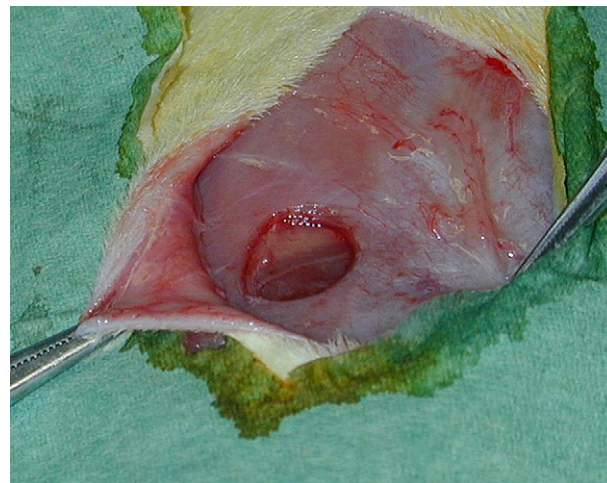

FIG. 1. Defects were created by resection of the rectus abdominis muscles using microsurgical technique 10 d before experimentation.

The rats were re-anesthetized 10 d after the creation of the defects, as described above. The skin incision was reopened, and the defects were examined macroscopically. The absence of defect closure and free accessibility to the peritoneum were confirmed in all the animals. Each rat received two samples: a TiMESH extralight fixed by Glubran2 (sample) and a TiMESH extralight fixed by traditional suture threads (control) were placed randomly on the left and on the right side of the abdomen.

Glubran2 was supplied by GEM S.r.l. (Viareggio, Italy) in the form of sterile liquid. The chemical structure of this adhesive for internal use is similar to n-butyl-2-cyanoacrylate, but it contains also a monomer additive synthesized by the manufacturer (methacryloxysulpholane) that decreases exothermic reaction during polymerization reducing the temperature to 45°C, reduces the cytotoxic effect, improves the elasticity and the bacteriostatic properties slightly extending the polymerization time [19].

The meshes were positioned over the hernias and used to close the defects. The sample meshes were glued with 30 μ L of Glubran2 according to the manufacturing instructions that suggest one drop per cm^2 , in particular 6 μ L of glue was applied by a micropipette in each corner and in the middle of the mesh (Fig. 2). To avoid adhesions to the implant, the skin was lifted for 90 s to allow the glue complete polymerization. The reference mesh was secured by four interrupted 3.0 Polysorb sutures (at each edge) on rectus muscles. Skin closure was obtained using interrupted 2.0 Maxon sutures. After operation antibiotic (Baytril) was administered to each animal for 7 d according to the Italian guidelines for animal care (DL 116/92). The rats were single-caged and checked daily for signs of cutaneous infection, inflammation, and seroma formation.

At the predetermined time points, rats were euthanized by isoflurane overdose.

Macroscopic Evaluation

The skin incision was reopened, and the macroscopical status of the implant site was assessed. If opaque glue residues were present (clearly distinguishable to the naked eye), the defects were rated P for “Present.” If no residues could be found macroscopically, the meshes were rated A for “Absent.” Finally, the meshes with surrounding muscular tissue were harvested and fixed in 10% buffered formalin for histological and immunohistochemical examinations.

Histology

Fixed specimens were embedded in paraffin and cut into 7 μ m sections. After haematoxylin and eosin (H an E, Bio-Optica, Milano,

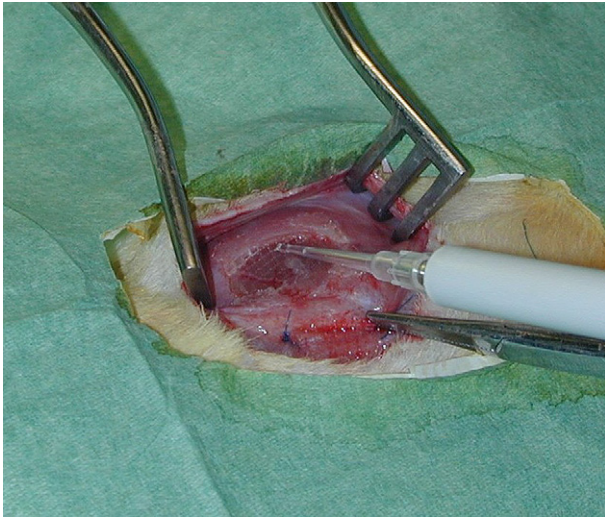


FIG. 2. The sample meshes were glued with five drops of Glubran2 applied by a micropipette (on the top), while the control mesh was secured by four interrupted 3.0 Polysorb sutures (at each edge) on rectus muscles (on the bottom; only two suture threads are visible).

Italy) stained sections were examined by Axiophot 2 microscope (Carl Zeiss, Oberkochen, Germany). Analysis was performed by an experienced pathologist who was not aware of the randomization protocol. Samples were screened for pathologic characteristics of inflammation and foreign body reaction elicited by residual glue. Findings were scored qualitatively as 0 (none), 1 (mild), or 2 (severe).

Immunohistochemistry

For the detection of DNA fragmentation in apoptotic cells, ApopTag peroxidase *in situ* apoptosis detection kit (Chemicon International Inc., Temecula, CA) was employed. Briefly, the reagents provided in ApopTag Kit are designed to label the free 3'-OH DNA termini *in situ* with chemically labeled and unlabeled nucleotides. The nucleotides contained in the reaction buffer are enzymatically added to the DNA by terminal deoxynucleotidyl transferase (TdT). TdT catalyzes a template-independent addition of nucleotide triphosphates to the 3'-OH ends of double-stranded or single-stranded DNA, that are very high concentrations of 3'-OH ends in apoptotic bodies. DNA fragments that have been labeled with the digoxigenin-nucleotide are then allowed to bind an anti-digoxigenin antibody that is conjugated to a peroxidase reporter molecule. The bound peroxidase antibody conjugate enzymatically generates a localized brown stain from diaminobenzidine (DAB) chromogenic substrates.

Sections were counterstained by light green FS yellowish that stains normal nuclei in green. Apoptosis was assessed by observing ApopTag-positive cells on histologic sections. Negative control sections were not treated by TdT enzyme, while sections pretreated with DNase I supplied positive control.

RESULTS

Macroscopic Evaluation

No intraoperative complications occurred. All rats had an uneventful recovery and remained free from infection and disturbance of wound healing. No seroma formation was observed. No detachment between mesh and underlining tissue was observed in Glubran2 fixed samples at all time points (Fig. 3), while in the

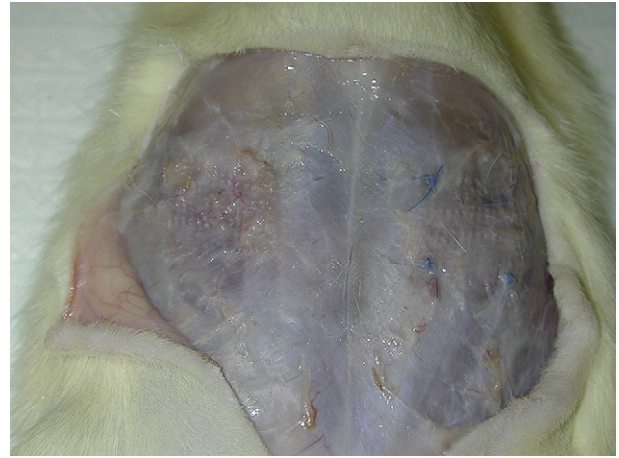


FIG. 3. Macroscopic observation of glued mesh (left) and sutured mesh (right) at 28 d of implant. Both samples appear firmly attached to underlining tissues, without seroma or macroscopic sign of inflammatory reaction.

control group, at earlier time points in some cases, the edges of the mesh were released from tissue.

All the defects were rated P because glue residues were still present at autopsy at each time points. These areas appeared as pale yellow irregular residues localized at the sites of original application.

Histology-Immunohistochemistry

Histology examination showed signs of mild inflammation (1 scored) in all glued samples similar to traditionally sutured meshes. Tissue healing was not affected by the glue presence and it was comparable to control sutured meshes at each time points (17 and 28 d, 3, 4, and 5 mo). The inflammatory reaction was constituted by a small number of macrophages and giant cells and vascularized connective tissue around glue residues and mesh threads (Fig. 4). No PMN, necrotic, or apoptotic cells were observed (Fig. 5). These results are compatible with the presence of a permanent stimulus induced by a biocompatible implantable material such as polypropylene.

DISCUSSION

Tissue adhesives have been proposed as an alternative to permanent fixation devices in hernia repair with the aim of reducing perforation-associated complications and chronic pain. The adhesives can be divided into three main categories: biologic products (e.g., fibrin), synthetic glues (e.g., cyanoacrylate based), and genetically engineered polymer protein glues [8].

Fibrin sealant has been used extensively in all surgical disciplines for tissue adhesion, suture support, hemostasis, wound care, and endoscopic treatment of bleeding [20–24].

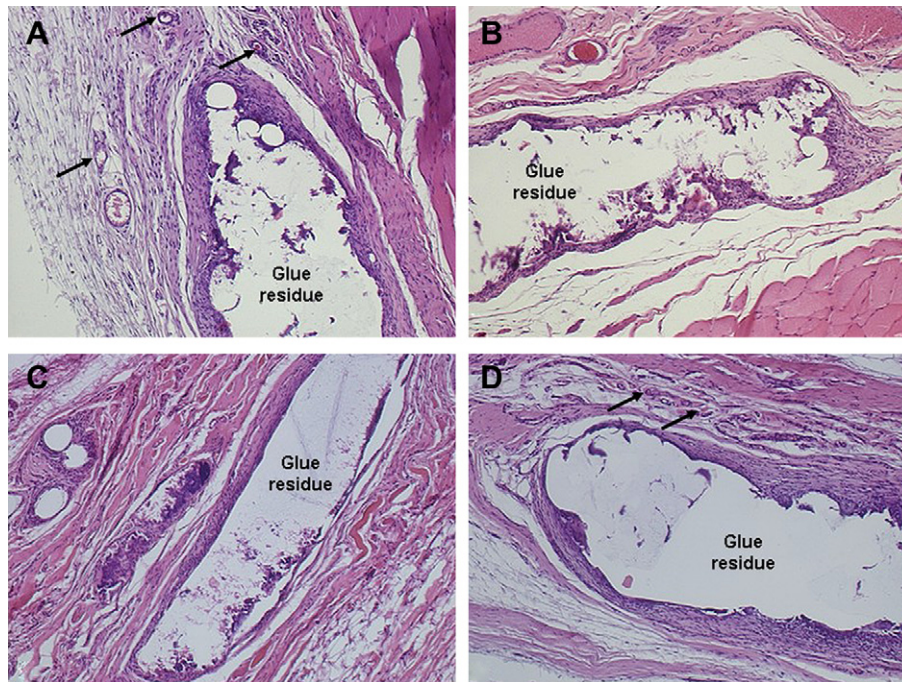


FIG. 4. H & E staining showed signs of slight inflammation (1 scored) in all glued samples at 17 d (A), 28 d (B), 4 mo (C), and 5 mo (D). The inflammatory reaction was constituted of a small number of macrophages around glue residues (visible at each time point) and mesh threads. The granulation tissue appears neovascularized (black arrows indicate capillaries).

Cyanoacrylate based glues have been investigated in numerous scientific studies as hemostatic agents, topical dressing, and adhesives in soft tissues, in ophthalmology, odontostomatology, osteosynthesis of bone fracture and, recently, as drug carriers [25–28]. They were also used in gastroenterology for esophagus varix treatment, in maxillo-facial surgery, and in vascular surgery for arterious anastomoses [29, 30].

After cyanoacrylate adhesives were used in humans and animals, some authors have found inflammatory responses, delayed healing, necrosis, and even bone destruction, while other authors have noticed a relative compatibility of polymerized cyanoacrylate with the surrounding tissues, resulting in normal healing processes of the injury. The shorter-chain cyanoacrylate

(methyl- and ethyl-cyanoacrylate) have proven to be intensely necrotizing and pyogenic and to stimulate an acute severe inflammatory response, whereas longer-chain cyanoacrylate (butyl- and isobutyl-cyanoacrylates) evoke only mild transient inflammation when applied to various tissues in the rabbit [31]. The length of the alkyl chain determines toxicity, in fact the higher molecular weight monomers are in general less toxic because they are depredated more slowly than the short-chain cyanoacrylate [32]. The observed toxicity was attributed to the adhesive heat of polymerization and/or degradation products such as formaldehyde and alkyl cyanoacetate [31]. When a series of cyanoacrylates adhesives was tested for local toxicity on rabbit, the butyl adhesive was consistently found to

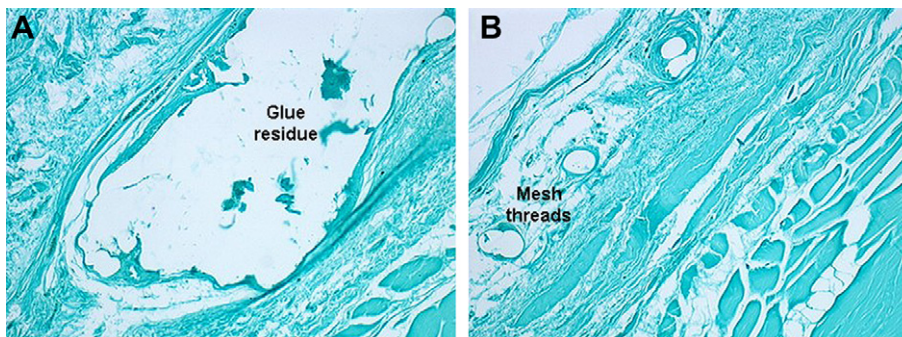


FIG. 5. ApopTag staining showed the absence of necrotic and apoptotic cells (no brown nuclei are observed) around glue residues (A) or mesh threads (B).

be less toxic than cyanoacrylates with methyl and ethyl radicals [33].

More recently, n-butyl-2-cyanoacrylate tissue adhesive demonstrated its safety and efficacy *in vitro* and *in vivo* showing low cytotoxicity and high adhesive properties [34, 35].

Concerning the adhesive use in mesh fixation, the beneficial effects of fibrin sealant have been reported in both experimental and clinical hernia repair [36–39]. However, data on cyanoacrylate glues for mesh fixation are still limited, but the capability of such substances to bond with enormous strength in a wet environment, as well as their bacteriostatic activities, have stimulated continuous research on their potential clinical applications [17, 18].

Moreover, in contrast to traditional mesh fixation, cyanoacrylate glue fixation avoids the risk of periostitis and muscle ischemia, is painless, prevents hernia relapse, and provides a sterile occlusive dressing. Finally, the use of tissue adhesive for tension-free mesh repair of abdominal hernia provides the advantages of this technique avoiding the potential problems associated with use of sutures or staples, such as the risk of injury to the patient or surgeon [40, 41].

The method described in this work is based on hernia repair using a modified n-butyl-2-cyanoacrylate glue instead of sutures or staples for abdominal mesh fixation. This surgical product polymerizes quickly (1–2 s to 1 min) when in contact with blood and tissues, allowing a rapid tissue closure and creating a thin elastic film with high stretch resistance that guarantees solid adhesion of the tissues [42].

In this study, extralight polypropylene meshes were fixed by Glubran2 or traditional stitches to repair abdominal defects in rat animal model. The *in vivo* experiments were carried out up to 5 mo. Some residues of glue films were found at each time point, demonstrating a low glue degradation rate.

We assumed as physiologic wound healing model, the tissue surrounding polypropylene mesh fixed with suture threads, which represents the present gold-standard in hernia repair. Then we compared the inflammatory reaction around polypropylene mesh fixed with suture threads and polypropylene mesh fixed with glue. The results from histologic analysis demonstrated that the degree of tissue integration and the inflammatory reaction around mesh threads was similar for the two study groups, without remarkable difference between glue or stitches fixed meshes.

Immunohistochemical analysis confirmed the histologic results; in fact no apoptotic cells were observed in all the glued samples. The absence of apoptotic cells correlates with the small number of granulocytes around mesh threads as observed in previous study [43].

Moreover, in this work it was demonstrated that an excellent mesh fixation was obtained employing a small right glue amount (30 μ L of glue applied in the corners and in the middle), that rapidly polymerizes without interfering with the physiologic wound healing. For this reason surgeons should avoid excessive and useless application of large glue amount that may lead to severe inflammatory reaction and poor wound healing as observed in another experimental study [16].

The mild inflammatory reaction here observed can be explained with the low polymerization temperature (45 °C) generated by Glubran2 with respect to other commercially used cyanoacrylates [34]; in fact it is known that high polymerization temperatures affect the host tissue, inducing local inflammation and necrosis [31].

In conclusion, on the basis of these experimental results, the use of a right amount of Glubran2 can effectively replace traditional suture threads in fixing abdominal mesh, guaranteeing a long-term firm adhesion without increasing inflammatory reaction respect to mesh fixed in traditional way.

Now that the potential of this method of mesh fixation has been established, Glubran2 should be used to perform a prospective randomized trial comparing the long-term results of adhesive mesh repair with those of the traditional sutured technique.

REFERENCES

1. McGreevy JM, Goodney PP, Birkmeyer CM, et al. A prospective study comparing the complication rates between laparoscopic and open ventral hernia repairs. *Surg Endosc* 2003;17:1778.
2. Neumayer L, Giobbie-Hurder A, Jonasson O, et al. Open mesh *versus* laparoscopic mesh repair of inguinal hernia. *N Engl J Med* 2004;350:1819.
3. Fitzgibbons RJ Jr, Salerno GM, Filipi CJ, et al. A laparoscopic intraperitoneal onlay mesh technique for the repair of an indirect inguinal hernia. *Ann Surg* 1994;219:144.
4. Katkhouda N, Campos GM, Mavor E, et al. Laparoscopic extraperitoneal inguinal hernia repair: A safe approach based on the understanding of rectus sheath anatomy. *Surg Endosc* 1999;13:1243.
5. Powell JJ, Murray GD, O'Dwyer PJ. Evaluation of staples and prostheses for use in laparoscopic inguinal hernia repair. *J Laparoendosc Surg* 1994;4:109.
6. Phillips EH, Arregui M, Carroll BJ, et al. Incidence of complications following laparoscopic hernioplasty. *Surg Endosc* 1995;9:16.
7. Sayad P, Hallak A, Ferzli G. Laparoscopic herniorrhaphy: Review of complications and recurrence. *J Laparoendosc Adv Surg Tech* 1998;8:3.
8. Cuschieri A. Tissue adhesives in endosurgery. *Semin Laparosc Surg* 2001;8:63.
9. Katkhouda N, Mavor E, Friedlander MH, et al. Use of fibrin sealant for prosthetic mesh fixation in laparoscopic extraperitoneal inguinal hernia repair. *Ann Surg* 2001;233:18.
10. Langrehr JM, Schmidt SC, Neuhaus P. Initial experience with the use of fibrin sealant for the fixation of the prosthetic mesh in laparoscopic transabdominal preperitoneal hernia repair. *Rozhl Chir* 2005;84:399.
11. Petter-Puchner A, Fortelny R, Mittermayr R, et al. Fibrin sealing vs stapling of hernia meshes in an onlay model in the rat. *Hernia* 2005;9:322.

12. Birch DW, Park A. Octylcyanoacrylate tissue adhesive as an alternative to mechanical fixation of expanded polytetrafluoroethylene prosthesis. *Am Surg* 2001;67:974.
13. Jourdan IC, Bailey ME. Initial experience with the use of N-butyl-2-cyanoacrylate glue for the fixation of polypropylene mesh in laparoscopic hernia repair. *Surg Laparosc Endosc* 1998;8:291.
14. Leggat PA, Kedjarune U, Smith DR. Toxicity of cyanoacrylate adhesives and their occupational impacts for dental staff. *Ind Health* 2004;42:207.
15. Nowobilski W, Dobosz M, Wojciechowicz T, et al. Lichtenstein inguinal hernioplasty using butyl-2-cyanoacrylate *versus* sutures: Preliminary experience of a prospective randomized trial. *Eur Surg Res* 2004;36:367.
16. Fortelny RH, Petter-Puchner AH, Walder N, et al. Cyanoacrylate tissue sealant impairs tissue integration of macroporous mesh in experimental hernia repair. *Surg Endosc* 2007;21:1781.
17. Ladurner R, Drosse I, Seitz S, et al. Tissue attachment strength and adhesion formation of intra-abdominal fixed meshes with cyanoacrylate glues. *Eur J Med Res* 2008;26:185.
18. Nowobilski W, Dobosz M, Wojciechowicz T, et al. Lichtenstein inguinal hernioplasty using butyl-2-cyanoacrylate *versus* sutures. Preliminary experience of a prospective randomized trial. *Eur Surg Res* 2004;36:367.
19. Leonardi M, Barbara C, Simonetti L, et al. Glubran 2: A new acrylic glue for neuroradiological endovascular use. *Intevent Neuroradiol* 2002;8:245.
20. Schexneider KI. Fibrin sealants in surgical or traumatic hemorrhage. *Curr Opin Hematol* 2004;11:323.
21. Lee MG, Provost DA, Jones DB. Use of fibrin sealant in laparoscopic gastric bypass for the morbidly obese. *Obes Surg* 2004;14:1321.
22. Shekarriz B, Stoller ML. The use of fibrin sealant in urology. *J Urol* 2002;167:1218.
23. Morikawa T. Tissue sealing. *Am J Surg* 2001;182:29S.
24. Mankad PS, Codispoti M. The role of fibrin sealants in hemostasis. *Am J Surg* 2001;182:21S.
25. Petersen B, Barkun A, Carpenter S, et al. Tissue adhesives and fibrin glues. *Gastrointest Endosc* 2004;60:327.
26. Müller RH, Lherm C, Herbort J, et al. *In vitro* model for the degradation of alkylcyanoacrylate nanoparticles. *Biomaterials* 1990;11:590.
27. Kubiak C, Couvreur P, Manil L, et al. Increased cytotoxicity of nanoparticle-carried Adriamycin *in vitro* and potentiation by verapamil and amiodarone. *Biomaterials* 1989;10:553.
28. Capasso G, Bentivoglio G, Testa V, et al. Osteosynthesis with an adhesive in skeletal fractures: An experimental study. *Arch Putti Chir Organi Mov* 1991;39:309.
29. D'Imperio N, Piemontese A, Baroncini D, et al. Evaluation of undiluted N-butyl-2-cyanoacrylate in the endoscopic treatment of upper gastrointestinal tract varices. *Endoscopy* 1996;28:239.
30. Saba D, Yilmaz M, Yavuz H, et al. Sutureless vascular anastomoses by N-butyl-2 cyanoacrylate adhesive: An experimental animal study. *Eur Surg Res* 2007;39:239.
31. Toriumi DM, Raslan WF, Friedman M, et al. Histotoxicity of cyanoacrylate tissue adhesives. A comparative study. *Arch Otolaryngol Head Neck Surg* 1990;116:546.
32. Vinters HV, Galil KA, Lundie MJ, et al. The histotoxicity of cyanoacrylates. A selective review. *Neuroradiology* 1985;27:279.
33. Gottlob R, Blumel G. The toxic action of alkylcyanoacrylate adhesives on vessels. Comparative studies. *J Surg Res* 1967;7:362.
34. Montanaro L, Arciola CR, Cenni E, et al. Cytotoxicity, blood compatibility and antimicrobial activity of two cyanoacrylate glues for surgical use. *Biomaterials* 2001;22:59.
35. Tebala GD, Ceriati F, Ceriati E, et al. The use of cyanoacrylate tissue adhesive in high-risk intestinal anastomoses. *Surg Today* 1995;25:1069.
36. Lovisetto F, Zonta S, Rota E, et al. Use of human fibrin glue (Tissucol) *versus* staples for mesh fixation in laparoscopic transabdominal preperitoneal hernioplasty: A prospective, randomized study. *Ann Surg* 2007;245:222.
37. Schug-Pass C, Lippert H, Köckerling F. Fixation of mesh to the peritoneum using fibrin glue: Investigations with a biomechanical model and an experimental laparoscopic porcine model. *Surg Endosc* 2009 (in press).
38. Schug-Pass C, Lippert H, Köckerling F. Mesh fixation with fibrin glue [Tissucol/Tisseel(R)] in hernia repair dependent on the mesh structure-is there an optimum fibrin-mesh combination?-Investigations on a biomechanical model. *Langenbeck's Arch Surg* 2009 (in press).
39. Schwab R, Schumacher O, Junge K, et al. Fibrin sealant for mesh fixation in Lichtenstein repair: Biomechanical analysis of different techniques. *Hernia* 2007;11:139.
40. Jourdan IC, Bailey ME. Initial experience with the use of N-butyl 2-cyanoacrylate glue for the fixation of polypropylene mesh in laparoscopic hernia repair. *Surg Laparosc Endosc* 1998;8:291.
41. Topart P, Vandenbroucke F, Lozac'h P. Tisseel *versus* tack staples as mesh fixation in totally extraperitoneal laparoscopic repair of groin hernias: A retrospective analysis. *Surg Endosc* 2005;19:724.
42. Kull S, Martinelli I, Briganti E, et al. Glubran2 surgical glue: *In vitro* evaluation of adhesive and mechanical properties. *J Surg Res* 2009;157:15.
43. Klinge U, Junge K, Stumpf M, et al. Functional and morphological evaluation of a low-weight, monofilament polypropylene mesh for hernia repair. *J Biomed Mater Res* 2002;63:129.